



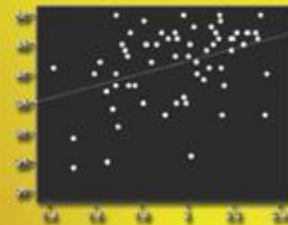
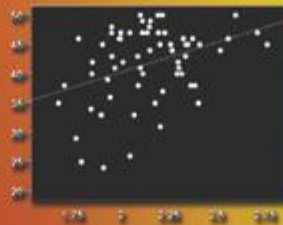
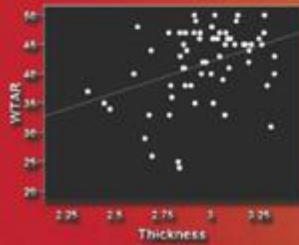
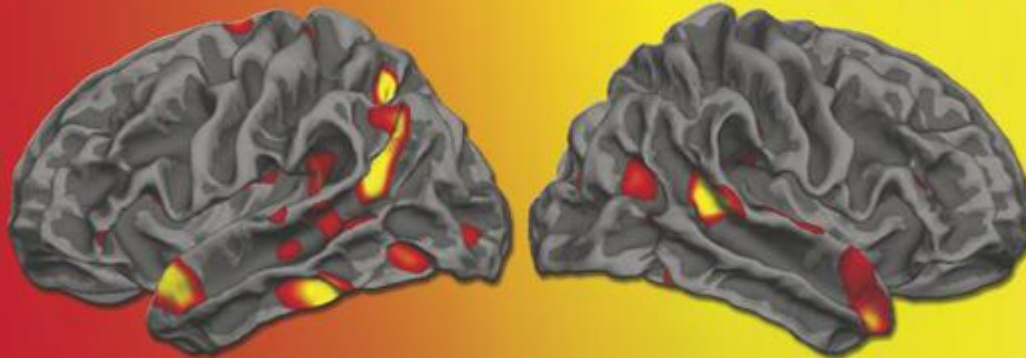
ISSN 1053-8119
This Issue Completes Volume 51
Volume 51, Issue 4, July 15, 2010

NeuroImage

Editor-in-Chief
Paul Fletcher

LEICESTER
SQUARE WC2
CITY OF WESTMINSTER

BOROUGH OF HOLBORN
OLD GLOUCESTER ST. W.C.



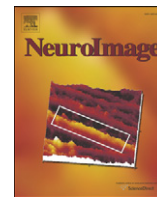
Available online at www.sciencedirect.com

ScienceDirect



Contents lists available at ScienceDirect

NeuroImage

journal homepage: www.elsevier.com/locate/ynimg

Phonetically irregular word pronunciation and cortical thickness in the adult brain

Karen Blackmon^a, William B. Barr^a, Ruben Kuzniecky^a, Jonathan DuBois^a, Chad Carlson^a, Brian T. Quinn^a, Mark Blumberg^a, Eric Halgren^b, Donald J. Hagler^b, Mark Mikhly^a, Orrin Devinsky^a, Carrie R. McDonald^b, Anders M. Dale^b, Thomas Thesen^{a,b,*}

^a Comprehensive Epilepsy Center, Department of Neurology, New York University, New York, NY, USA

^b Multimodal Imaging Laboratory, University of California, San Diego, CA, USA

ARTICLE INFO

Article history:

Received 4 January 2010

Revised 24 February 2010

Accepted 9 March 2010

Available online 17 March 2010

Keywords:

Cortical thickness

Dyslexia

Reading

Exception words

ABSTRACT

Accurate pronunciation of phonetically irregular words (exception words) requires prior exposure to unique relationships between orthographic and phonemic features. Whether such word knowledge is accompanied by structural variation in areas associated with orthographic-to-phonemic transformations has not been investigated. We used high-resolution MRI to determine whether performance on a visual word-reading test composed of phonetically irregular words, the Wechsler Test of Adult Reading (WTAR), is associated with regional variations in cortical structure. A sample of 60 right-handed, neurologically intact individuals were administered the WTAR and underwent 3 T volumetric MRI. Using quantitative, surface-based image analysis, cortical thickness was estimated at each vertex on the cortical mantle and correlated with WTAR scores while controlling for age. Higher scores on the WTAR were associated with thicker cortex in bilateral anterior superior temporal gyrus, bilateral angular gyrus/posterior superior temporal gyrus, and left hemisphere intraparietal sulcus. Higher scores were also associated with thinner cortex in left hemisphere posterior fusiform gyrus and central sulcus, bilateral inferior frontal gyrus, and right hemisphere lingual gyrus and supramarginal gyrus. These results suggest that the ability to correctly pronounce phonetically irregular words is associated with structural variations in cortical areas that are commonly activated in functional neuroimaging studies of word reading, including areas associated with grapheme-to-phonemic conversion.

© 2010 Elsevier Inc. All rights reserved.

Introduction

Substantial progress has been made in identifying the key neuroanatomical substrates of reading. In contrast to a large number of functional neuroimaging studies on word reading networks, there have been relatively few investigations of structural variations associated with reading proficiency (Richardson and Price, 2009). The current study was designed to investigate whether structural variations associated with oral reading proficiency can be observed in nonimpaired individuals and whether regional variation in cortical thickness corresponds to neuroanatomical areas previously implicated in functional and structural neuroimaging studies of normal reading pathways.

Recent advances in neuroimaging have contributed significantly to the understanding of the associations between specific brain areas and reading function. Functional imaging studies of nonimpaired individuals consistently identify several left-lateralized and bilateral regions despite variations in task design and post-processing procedures (Fiez and Petersen, 1998; Turkeltaub et al., 2002). These

regions of the so-called reading network include occipital and occipitotemporal cortex, the left frontal operculum, bilateral regions within the cerebellum, primary motor cortex, the superior and middle temporal cortex, and medial regions in the supplementary motor area and anterior cingulate. Meta-analytic comparison of alphabetic, syllabic, and morpho-syllabic reading systems revealed common activations in the left superior posterior temporal gyrus, the left inferior frontal gyrus, and the left occipitotemporal region (Bolger et al., 2005), regions of the reading network that were found to be functionally correlated even at rest (Koyama et al., 2010).

Comparison of specific reading strategies has identified dissociable networks for word decoding and whole word retrieval. Brain areas implicated during graphophonological conversion usually include left-hemisphere regions, such as superior temporal areas, supramarginal gyrus, and the opercular part of inferior frontal gyrus; whereas tasks requiring lexicosemantic access consistently activate left occipitotemporal, middle temporal gyrus and the pars triangularis of the inferior frontal gyrus (Jobard et al., 2003; Pugh et al., 2000). Phonetically irregular word reading activates the left frontal operculum relative to phonetically regular word reading (Fiez and Petersen, 1998). Greater supramarginal/angular gyrus and superior temporal gyrus activation is associated with graphophonological conversion

* Corresponding author. Department of Neurology, New York University, 223 East 34th Street, New York, NY 10016, USA. Fax: +1 917 829 2016.

E-mail address: thomas.thesen@med.nyu.edu (T. Thesen).

tasks (Booth et al., 2002a,b, 2003). The latter findings suggest that inferior parietal areas maintain a specialized role in extracting statistical regularities between orthographic and phonetic word features (Booth et al., 2004).

Fewer studies have looked at the structural correlates of reading. Group studies of dyslexic and unimpaired readers that use voxel-based morphometry (VBM) and diffusion tensor imaging (DTI) show reduced gray matter density in the left inferior, middle, and superior temporal gyri (Brown et al., 2001; Vinckenbosch et al., 2005), decreased fractional anisotropy (FA) in bilateral fronto-temporal and left temporo-parietal white matter regions, and reduced gray matter volume in bilateral superior temporal gyri (Steinbrink et al., 2008), as well as reduced gray matter volume in bilateral fusiform gyri, anterior cerebellum, and right supramarginal gyrus (Kronbichler et al., 2008). This overlap with areas of the functional reading network indeed suggests a link between regional brain morphology and function. In a study combining functional magnetic resonance imaging (fMRI) and VBM (Hoeft et al., 2007), it showed that the left parietal and bilateral fusiform cortices of individuals with dyslexia activate less compared to typically developing readers, a pattern that was accompanied by reduced gray matter volume in the left parietal, but not the fusiform regions. Similarly, PET and VBM analyses in two separate studies revealed reduced activation in left temporal and temporal-occipital regions in dyslexic adults from three different countries (Paulesu et al., 2001), along with reduced gray matter density in left middle temporal gyrus and reduced white matter density in the depth of left Broca's area, left post-central gyrus, and supramarginal gyrus (Silani et al., 2005). These findings are supported by post-mortem findings of small pathological ectopias and dysplasias in individuals with developmental dyslexia, located throughout the inferior left frontal, superior left temporal, and right frontal regions (Galaburda et al., 1985; Rosen et al., 1993).

Structural imaging studies of reading performance in nonimpaired populations are more sparse, but do support the shared structure-function hypothesis. For example, faster reading speeds have been associated with increased gray matter density and higher FA values in left frontal regions (Steinbrink et al., 2008), whereas increased local gray matter volume (LGMV) in perisylvian areas and reduced LGMV in inferior temporal areas (including fusiform gyrus) correlates with better pseudoword reading performance (Pernet et al., 2009). Intriguingly, structural comparisons between individuals who learned to read as adults and matched illiterates revealed increased white matter in the splenium of the corpus callosum and increased gray matter in bilateral angular gyri, dorsal occipital, middle temporal, left supramarginal, and superior temporal gyri (Carreiras et al., 2009), suggesting that experience and proficiency can effect structural changes in areas of the reading network even in adulthood.

The current study explores whether variations in cortical thickness are associated with exception word reading, a skill that involves the acquisition of unique associations between visual and auditory features. Exception words, or phonetically irregular words, are words that do not follow typical phonetic rules (for example: *gnat*, *porpoise*, *ogre*, *aisle*, *paradigm*). Exception word reading, in contrast to pseudoword decoding, must involve prior exposure to unique grapheme-to-phoneme relationships and is therefore well suited to investigate whether (a) exposure/learning is associated with structural variations in classic reading networks, and more specifically (b) whether such structural differences are located in areas associated with rapid word identification (ventral route, occipito-temporal areas) and/or areas associated with the integration of orthographic with phonological and lexical-semantic features (dorsal route, inferior parietal areas). In line with prior work that demonstrates structural differences between late-literates and illiterates in bilateral inferior parietal areas and the splenium of the corpus callosum (Carreiras et al., 2009), we predict that structural variations will be bilateral and homologous.

Materials and methods

Participants

A sample of 60 right-handed, neurologically intact individuals (age range: 19 to 66 years; $M = 36.4$, $SD = 13.3$, 32 females) gave consent to participate in the study. All participants were determined to be right-handed with the Edinburgh Handedness Inventory, with left-handedness defined as a score < 0 (Oldfield, 1971). Participants were determined to be free of schizophrenia, neurological disorders, and reading impairment in an initial screening interview where they were asked whether they had ever been diagnosed with a psychiatric illness, neurological illness, or learning disability. Group education level ranged from an eighth grade education to a graduate degree ($M = 14.0$, $SD = 2.4$). The study was approved by the Institutional Review Board of New York University.

Word reading assessment

All subjects completed The Wechsler Test of Adult Reading™ (WTAR™). This reading test is composed of a list of 50 words that have atypical grapheme to phoneme relationships. The WTAR was developed as a tool to estimate premorbid intellectual functioning in neurologically diseased populations. Words with irregular pronunciations were chosen in order to minimize the participant's ability to apply standard pronunciation rules, as well as to assess previous learning of the word. In a stratified US sample of 1,134 individuals ranging in age from 16 to 89, mean raw scores for each age group ranged from 24.8 ($SD = 7.9$) to 42.3 ($SD = 6.6$). The distribution of mean scores indicated a curvilinear pattern with gradual performance increases from the 16–17 age group to the 45–54 age group and gradual performance decreases from the 45–54 age group to the 84–89 age group. Internal consistency reliability coefficients were strong for each age group with an average of $r = 0.93$, as was test-retest stability for each age group with correlations ranging from $r = 0.92$ to $r = 0.94$ (Wechsler, 2001).

MRI scanning and image processing

Imaging was performed at the New York University Center for Brain Imaging on a 3 T Siemens Allegra head-only MR scanner. Image acquisitions included a conventional 3-plane localizer and two T_1 -weighted volumes ($TE = 3.25$ ms, $TR = 2530$ ms, $TI = 1.100$ ms, flip angle = 7 deg, field of view (FOV) = 256 mm, voxel size = $1 \times 1 \times 1.33$ mm). Acquisition parameters were optimized for increased gray/white matter image contrast. The imaging protocol was identical for all subjects studied. The image files in DICOM format were transferred to a Linux workstation for morphometric analysis. The two T_1 -weighted images were rigid body registered to each other and reoriented into a common space, roughly similar to alignment based on the AC-PC line. Images were automatically corrected for spatial distortion due to gradient nonlinearity (Jovicich et al., 2006) and B_1 field inhomogeneity (Sled et al., 1998), registered, and averaged to improve signal-to-noise ratio. Images were further processed with the FreeSurfer (4.0.2) software package (<http://surfer.nmr.mgh.harvard.edu>).

Surface reconstruction and thickness measurements

Cortical thickness is a measure derived from automated MRI post-processing procedures that segment the cerebral cortex and measure the distance between the pial surface and gray/white matter boundary (Dale et al., 1999). An advantage of surface- over volume-based approaches is the possibility of spherical averaging, which aligns sulcal and gyral patterns and thus allows for improved coregistration of brain structures across individual brains (Fischl et al., 1999). To this end, the averaged volumetric MRI scan was used

to construct models of each subject's cortical surface using an automated procedure that involves (1) segmentation of the white matter, (2) tessellation of the gray/white matter boundary, (3) inflation of the folded surface tessellation, and (4) automatic correction of topological defects. These steps are described in detail elsewhere (Dale et al., 1999; Fischl et al., 2001; Fischl et al., 1999). From this reconstructed surface, measures of cortical thickness were obtained by constructing an estimate of the gray/white matter boundary by classifying all white matter voxels in the MRI volume (Fischl and Dale, 2000). The white matter surface was refined in order to obtain submillimeter accuracy in delineating the gray/white matter junction. The surface was then deformed outward to locate the pial surface (Dale et al., 1999). Estimates of cortical thickness were made by measuring (1) the shortest distance from each point on the white matter surface to the pial surface, and (2) the shortest distance from each point on the pial surface to the white matter surface. Cortical thickness at each vertex was computed as the average of the two values. Maps were smoothed with a Gaussian kernel (15 mm FWHM) across the surface and averaged across participants using a spherical averaging technique (Fischl et al., 1999), which accurately matches anatomically homologous regions across participants while minimizing metric distortions. For each hemisphere, a general linear model was used to estimate the effects of WTAR performance on cortical thickness at each vertex along the cortical surface. Significance maps were corrected for multiple comparisons with cluster-based Monte-Carlo simulations with 10,000 permutations (Hayasaka and Nichols, 2003). Corrected significance values of thickness correlations with WTAR scores were mapped onto the white matter surface of the average brain reconstruction for visual display.

Results

Age and gender

WTAR scores in our sample ranged from 24 to 50 ($M=41.72$, $SD=6.43$). Given the adequate range and normal distribution of these scores, raw scores, as opposed to normatively corrected scores were used in additional analyses. Performance on the WTAR showed a moderate negative correlation with age ($r=-.39$, $p<.01$) (Fig. 1), a moderate positive correlation with education ($r=.36$, $p<.01$) and no difference between genders ($t(58)=-1.3$, $p=.2$; females: $M=42.72$, $SD=6.5$; males: mean=40.57, $SD=6.27$). Given the negative correlation between WTAR scores and age in our sample, as well as prior evidence of age-related decline in cortical thickness

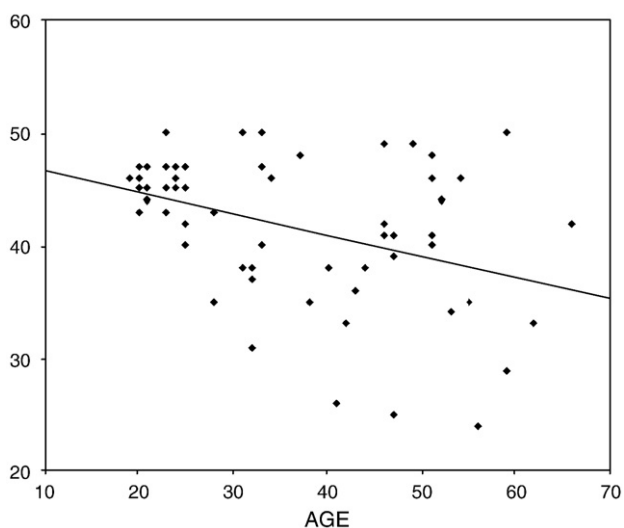


Fig. 1. Correlation of WTAR performance and age.

(Salat et al., 2004), an additional vertex-wise analysis of cortical thickness and WTAR was performed which controlled for age-related effects.

Cortical thickness

Several brain areas showed distinct structural differences associated with performance on a test of irregular word pronunciation (Fig. 2). Higher test performance was associated with thicker cortex, independent of age, in the intraparietal sulcus of the left hemisphere and the angular gyrus/posterior superior temporal gyrus area (AG/pSTG) and anterior STG (aSTG) bilaterally. Better performance was associated with decreased cortical thickness in left posterior fusiform gyrus (pFG), as well as inferior frontal gyrus (IFG) and central sulcus.

Discussion

Our results demonstrate that better performance on a phonetically irregular oral word reading task is associated bilaterally with increased cortical thickness in the angular gyrus/posterior superior temporal gyrus (AG/p-STG) and anterior superior temporal gyrus (aSTG), two well-established oral reading areas. The first is consistently implicated in orthographic-to-phonemic translation (Booth et al., 2002a,b) and the second in the analysis and categorization of speech sounds (Leff et al., 2009; Obleser et al., 2006). We also found a relationship between exception word knowledge and cortical thickness in the left superior parietal area/intraparietal sulcus (IPS), an area previously implicated in the spatial attention aspects of word reading (Baciu et al., 2002; Bitan et al., 2005).

These results are consistent with prior imaging studies that demonstrate greater volume or density in inferior parietal association cortex related to reading skill acquisition (Carreiras et al., 2009), vocabulary acquisition (Lee et al., 2007), the ability to pronounce novel words (Golestani and Pallier, 2007), and second language proficiency (Mechelli et al., 2004). In a comparison of late-literates to matched illiterates, inferior parietal areas were found to be greater in volume bilaterally, suggesting that this area may be critical for adult reading skill acquisition. Furthermore, increased functional connectivity between the left and right angular gyri was demonstrated during reading tasks in early literates, relative to object naming (Carreiras et al., 2009). This highlights the importance of inferior parietal regions in normal reading, despite inconsistent findings between functional and structural investigations. Specifically, in contrast to findings of reduced task-related activation in the left angular gyrus of dyslexic readers (Price and Mechelli, 2005; Richlan et al., 2009; Shaywitz et al., 1998), this area is not found to be strongly activated in functional neuroimaging of nonimpaired readers (Fiez and Petersen, 1998; Turkeltaub et al., 2003). Our results provide novel evidence that knowledge of unique grapheme-to-phoneme relationships is associated with increased cortical thickness in inferior and superior parietal areas, even in the absence of reading impairment.

Contrary to our hypotheses, we found an inverse relationship between skilled exception word reading and cortical thickness in bilateral inferior frontal gyri, right hemisphere lingual and supramarginal gyrus, and left hemisphere posterior fusiform gyrus and central sulcus. Activation of inferior frontal and primary motor areas is a consistent finding in functional neuroimaging studies of word reading (Fiez and Petersen, 1998; Turkeltaub et al., 2002), and the supramarginal gyrus is another region implicated in orthographic to phonemic translations (Booth et al., 2002a,b); however, it is not clear why reduced thickness in these areas might be associated with stronger performance. The fusiform gyrus is a key area implicated in studies involving rapid letter and word identification (McCandliss et al., 2003). Notably, an inverse relationship between fusiform gyrus volume and pseudoword reading performance was also found in a prior investigation (Pernet et al., 2009). Although different

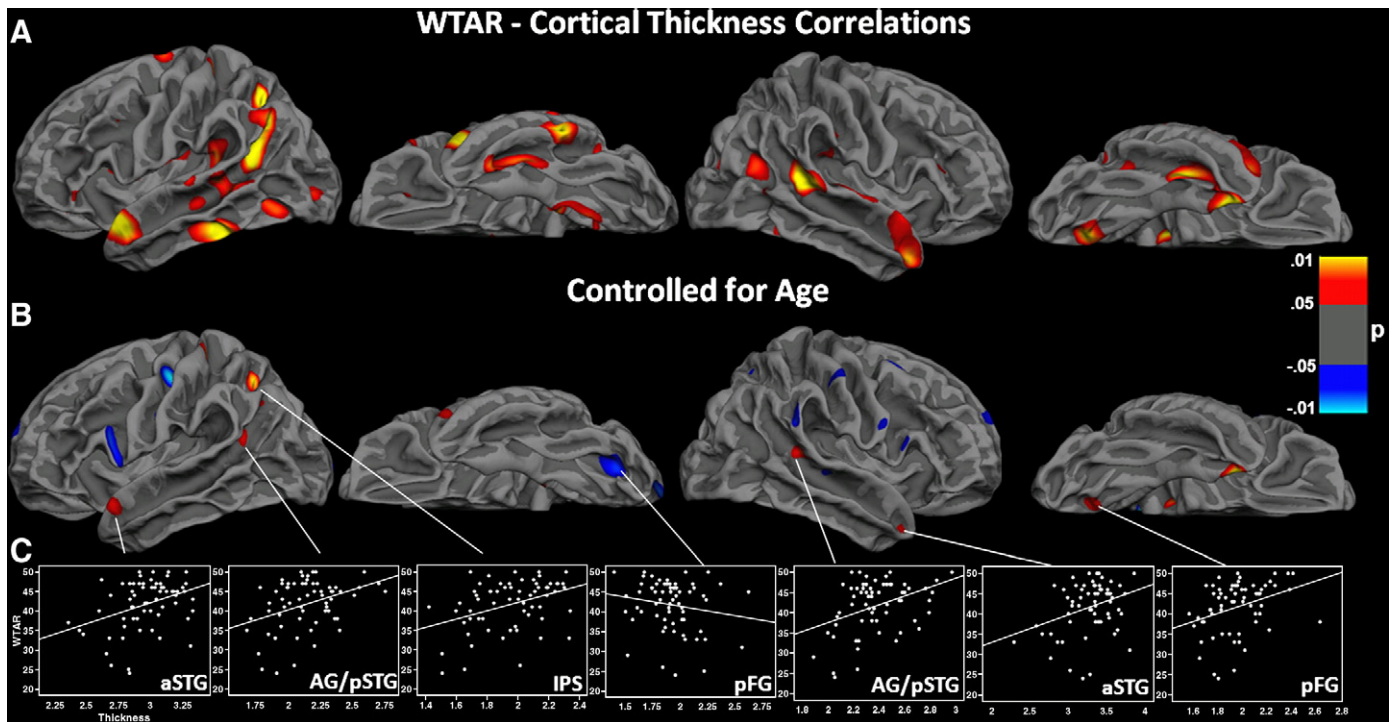


Fig. 2. Areas with significant WTAR and cortical thickness correlations displayed on the group-averaged white matter surface. Regions in red are positive (better performance with increased thickness) and regions in blue are negative (better performance with decreased thickness). Statistical P maps thresholded at $p < 0.05$, cluster-corrected. (A) Uncorrected for age-related changes. (B) Corrected for age. (C) Scatter plots with best fit line showing thickness (x-axis) and WTAR score (y-axis) for each participant in areas of significant correlation. (aSTG = anterior superior temporal gyrus; AG/pSTG = angular gyrus/posterior STG; IPS = intraparietal sulcus; pFG = posterior fusiform gyrus).

performance measures were used, this intriguing convergence between our morphological findings strengthens the claim that decreased gray matter in the the fusiform area is associated with improved functional integrity.

When considered in the context of prior functional imaging studies, our findings provide strong evidence for structural variations in classic reading areas associated with performance on an exception word reading test; however, the nature of these variations remains unclear. The underlying cellular properties that mediate the relationship between cortical thickness variations and word reading performance need to be investigated with post-mortem or post-resection histological studies. The cortical mantle contains cell bodies of various neuron types, neuronal synapses, axons, etc., and variation in any of these could influence both structural and functional properties of an area. Cortical thickening in some regions may reflect experience-dependent dendritic branching; however, such mechanisms remain unknown. Although there is evidence that cortical thickening is associated with learning/practice within a specific domain (Haier et al., 2009), it is also possible that early structural differences in gray matter thickness may potentiate more efficient learning and memory of novel grapheme-to-phoneme relationships.

Likewise, the relationship between cortical thinning and stronger performance on cognitive tasks has been documented in prior studies (Dickerson et al., 2008; Lu et al., 2007; Shaw et al., 2006); however, it remains unclear why stronger performance may be associated with thinner cortex in select areas. Such relationships may be associated with the myelination process or synaptic pruning, particularly in earlier stages of development (Lu et al., 2007; Sowell et al., 2008; Sowell et al., 2004). Increased myelination in tertiary cortex, such as fusiform and lingual areas, may reflect the early development of expert systems for letter and word identification, while gray matter thickening in association cortex may reflect lifetime learning/acquisition of unique relationships between visual, auditory, and articulatory word features. Further research investigating how

developmental changes in gray matter properties and white matter tracts relate to oral reading skill acquisition is needed to clarify the complex relationships between regional cortical thickness and reading skill acquisition.

Several structural correlates in our study were bilateral and homologous, a finding which is consistent with other investigations of cortical thickness variations associated with language processing (Golestani and Pallier, 2007; Lee et al., 2007; Mechelli et al., 2004). Functional imaging studies commonly demonstrate bilateral activations in homologous areas during reading tasks, particularly in the superior temporal gyri (Fiez and Petersen, 1998; Turkeltaub et al., 2002). Although bilateral networks are activated during oral reading, left-hemisphere areas appear to be necessary while right hemisphere sites play a complementary or compensatory role (Roux et al., 2004). This is demonstrated in several studies where disruption of left hemisphere temporo-parietal networks is associated with reading impairment and an increase in reliance on right hemisphere and frontal networks (Coslett and Monsul, 1994; Horwitz et al., 1998; Pugh et al., 2000; Rumsey et al., 1997).

Dissociable reading networks have been proposed for reading strategies that involve effortful rule-based analysis (dorsal temporo-parietal stream) and automatic memory based whole word identification (occipito-temporal ventral stream) (Pugh et al., 2000). Our results demonstrate cortical thickening related to skilled pronunciation of phonetically irregular words in the angular gyrus/posterior superior temporal gyrus, an area previously associated with rule-based orthographic-to-phonemic analysis (Booth et al., 2004). This finding is consistent with a single area for acquisition of relationships between orthographic and phonemic word features, regardless of whether such relationships are unique, as in the case of exception words, or rule-based, as in the case of regular words or pseudowords. However, the current study was limited in that only a measure of exception word reading was administered. Future work should include comparison between structural correlates of pseudoword

reading and exception word reading to determine whether regional variations overlap or can be dissociated. This would be relevant for characterizing morphometric variations associated with different profiles of reading impairment, such as surface dyslexia or phonological dyslexia.

Limitations of the current study include a reliance on a single performance measure. This precludes any claim that the structural variations we found are related specifically to exception word reading and not other measures of reading and/or language acquisition. In fact, given results from other studies (Golestani and Pallier, 2007; H. Lee et al., 2007; Mechelli et al., 2004) (Golestani et al., 2002; Mechelli et al., 2004; Lee et al., 2007) it is likely that structural variation in the inferior parietal region is associated with many different aspects of language processing. Further limitations include minimal information regarding the level of intellectual functioning of our participants, their socioeconomic status, their reading history and habits (i.e. age of reading onset, reading frequency) as well as any family history of reading disabilities. It is recommended that future studies in this area include analyses of the relationship between such demographic variables and reading performance, as they may independently contribute to variance in structural and performance measures.

In sum, the current study is one of very few demonstrating structural correlates of reading performance in nonimpaired individuals and shows a clear association between exception word reading and cortical thickness in classic reading areas. Contrary to the assumption that more is better, stronger performance was associated with thinner cortex in critical reading areas such as the fusiform gyrus and the inferior frontal region. Such findings are valuable for designing future longitudinal work investigating structural changes accompanying normal reading skill acquisition or remediation efforts in individuals with reading impairment. As the nature of such regional structure–performance correlates becomes better defined, structural markers may predict the success of remediation efforts in individuals with developmental or acquired reading impairment.

Acknowledgments

Supported by faces (Finding a Cure for Epilepsy and Seizures) (T.T.) and NIH grants NS18741 (E.H.), NS44623 (E.H.) and NS056091 (C.M.).

References

- Baciu, M., Ans, B., Carbonnel, S., Valdois, S., Juphard, A., Pachot-Clouard, M., et al., 2002. Length effect during word and pseudo-word reading. An event-related fMRI study. *Neurosci. Res. Commun.* 30 (3), 155–165. doi:10.1002/nrc.10027.
- Bitan, T., Manor, D., Morocz, I.A., Karni, A., 2005. Effects of alphabeticality, practice and type of instruction on reading an artificial script: an fMRI study. *Brain Res. Cogn. Brain Res.* 25 (1), 90–106. doi:10.1016/j.cogbrainres.2005.04.014.
- Bolger, D.J., Perfetti, C.A., Schneider, W., 2005. Cross-cultural effect on the brain revisited: universal structures plus writing system variation. *Hum. Brain Mapp.* 25 (1), 92–104. doi:10.1002/hbm.20124.
- Booth, J.R., Burman, D.D., Meyer, J.R., Gitelman, D.R., Parrish, T.B., Mesulam, M.M., 2002a. Functional anatomy of intra- and cross-modal lexical tasks. *NeuroImage* 16 (1), 7–22. doi:10.1006/nimg.2002.1081.
- Booth, J.R., Burman, D.D., Meyer, J.R., Gitelman, D.R., Parrish, T.B., Mesulam, M.M., 2002b. Modality independence of word comprehension. *Hum. Brain Mapp.* 16 (4), 251–261. doi:10.1002/hbm.10054.
- Booth, J.R., Burman, D.D., Meyer, J.R., Gitelman, D.R., Parrish, T.B., Mesulam, M.M., 2003. Relation between brain activation and lexical performance. *Hum. Brain Mapp.* 19 (3), 155–169. doi:10.1002/hbm.10111.
- Booth, J.R., Burman, D.D., Meyer, J.R., Gitelman, D.R., Parrish, T.B., Mesulam, M.M., 2004. Development of brain mechanisms for processing orthographic and phonologic representations. *J. Cogn. Neurosci.* 16 (7), 1234–1249. doi:10.1162/0898929041920496.
- Brown, W.E., Eliez, S., Menon, V., Rumsey, J.M., White, C.D., Reiss, A.L., 2001. Preliminary evidence of widespread morphological variations of the brain in dyslexia. *Neurology* 56 (6), 781–783.
- Carreiras, M., Seghier, M.L., Baquero, S., Estevez, A., Lozano, A., Devlin, J.T., et al., 2009. An anatomical signature for literacy. *Nature* 461 (7266), 983–986. doi:10.1038/nature08461.
- Coslett, H.B., Monsul, N., 1994. Reading with the right hemisphere: evidence from transcranial magnetic stimulation. *Brain Lang.* 46 (2), 198–211. doi:10.1006/brln.1994.1012.
- Dale, A.M., Fischl, B., Sereno, M.I., 1999. Cortical surface-based analysis. I. Segmentation and surface reconstruction. *NeuroImage* 9 (2), 179–194. doi:10.1006/nimg.1998.0395.
- Dickerson, B., Fenstermacher, E., Salat, D., Wolk, D., Maguire, R., Desikan, R., et al., 2008. Detection of cortical thickness correlates of cognitive performance: reliability across MRI scan sessions, scanners, and field strengths. *NeuroImage* 39 (1), 10–18. doi:10.1016/j.neuroimage.2007.08.042.
- Fiez, J.A., Petersen, S.E., 1998. Neuroimaging studies of word reading. *Proc. Natl. Acad. Sci. U. S. A.* 95 (3), 914–921 (VL - 95).
- Fischl, B., Dale, A.M., 2000. Measuring the thickness of the human cerebral cortex from magnetic resonance images. *Proc. Natl. Acad. Sci. U. S. A.* 97 (20), 11050–11055. doi:10.1073/pnas.200033797.
- Fischl, B., Sereno, M.I., Dale, A.M., 1999. Cortical surface-based analysis. II: inflation, flattening, and a surface-based coordinate system. *NeuroImage* 9 (2), 195–207. doi:10.1006/nimg.1998.0396.
- Fischl, B., Liu, A., Dale, A.M., 2001. Automated manifold surgery: constructing geometrically accurate and topologically correct models of the human cerebral cortex. *IEEE Trans. Med. Imaging* 20 (1), 70–80. doi:10.1109/42.906426.
- Galaburda, A.M., Sherman, G.F., Rosen, G.D., Aboitiz, F., Geschwind, N., 1985. Developmental dyslexia: four consecutive patients with cortical anomalies. *Ann. Neurol.* 18 (2), 222–233. doi:10.1002/ana.410180210.
- Golestani, N., Paus, T., Zatorre, R.J., 2002. Anatomical correlates of learning novel speech sounds. *Neuron* 35 (5), 997–1010 PMID: 12372292.
- Golestani, N., Pallier, C., 2007. Anatomical correlates of foreign speech sound production. *Cereb. Cortex (New York, N.Y.: 1991)* 17 (4), 929–934. doi:10.1093/cercor/bhl003.
- Haier, R.J., Karama, S., Leyba, L., Jung, R.E., 2009. MRI assessment of cortical thickness and functional activity changes in adolescent girls following three months of practice on a visual-spatial task. *BMC Res. Notes* 2, 174. doi:10.1186/1756-0500-2-174.
- Hayasaka, S., Nichols, T.E., 2003. Validating cluster size inference: random field and permutation methods. *NeuroImage* 20 (4), 2343–2356.
- Hoefl, F., Meyler, A., Hernandez, A., Juel, C., Taylor-Hill, H., Martindale, J.L., et al., 2007. Functional and morphometric brain dissociation between dyslexia and reading ability. *Proc. Natl. Acad. Sci.* 104 (10), 4234–4239. doi:10.1073/pnas.0609399104.
- Horwitz, B., Rumsey, J.M., Donohue, B.C., 1998. Functional connectivity of the angular gyrus in normal reading and dyslexia. *Proc. Natl. Acad. Sci. U. S. A.* 95 (15), 8939–8944 (VL - 95).
- Jobard, G., Crivello, F., Tzourio-Mazoyer, N., 2003. Evaluation of the dual route theory of reading: a meta-analysis of 35 neuroimaging studies. *NeuroImage* 20 (2), 693–712. doi:10.1016/S1053-8119(03)00343-4.
- Jovicich, J., Czanner, S., Greve, D., Haley, E., van der Kouwe, A., Gollub, R., et al., 2006. Reliability in multi-site structural MRI studies: effects of gradient non-linearity correction on phantom and human data. *NeuroImage* 30 (2), 436–443. doi:10.1016/j.neuroimage.2005.09.046.
- Koyama, M.S., Kelly, C., Shehzad, Z., Penesetti, D., Castellanos, F.X., Milham, M.P., 2010. Reading Networks at Rest. *Cereb. Cortex.* doi:10.1093/cercor/bhq005 (bhq005).
- Kronbichler, M., Wimmer, H., Staffen, W., Hutzler, F., Mair, A., Ladurner, G., 2008. Developmental dyslexia: gray matter abnormalities in the occipitotemporal cortex. *Hum. Brain Mapp.* 29 (5), 613–625. doi:10.1002/hbm.20425.
- Lee, H., Devlin, J.T., Shakeshaft, C., Stewart, L.H., Brennan, A., Glensman, J., et al., 2007. Anatomical traces of vocabulary acquisition in the adolescent brain. *J. Neurosci.* 27 (5), 1184–1189. doi:10.1523/JNEUROSCI.4442-06.2007.
- Leff, A.P., Iverson, P., Schofield, T.M., Kilner, J.M., Crinion, J.T., Friston, K.J., et al., 2009. Vowel-specific mismatch responses in the anterior superior temporal gyrus: an fMRI study. *Cortex* 45 (4), 517–526. doi:10.1016/j.cortex.2007.10.008.
- Lu, L., Leonard, C., Thompson, P., Kan, E., Jolley, J., Welcome, S., et al., 2007. Normal developmental changes in inferior frontal gray matter are associated with improvement in phonological processing: a longitudinal MRI analysis. *Cereb. Cortex* 17 (5), 1092–1099. doi:10.1093/cercor/bhl019.
- McCandliss, B.D., Cohen, L., Dehaene, S., 2003. The visual word form area: expertise for reading in the fusiform gyrus. *Trends Cogn. Sci.* 7 (7), 293–299. doi:10.1016/S1364-6613(03)00134-7.
- Mechelli, A., Crinion, J.T., Noppeney, U., O'Doherty, J., Ashburner, J., Frackowiak, R.S., et al., 2004. Neurolinguistics: structural plasticity in the bilingual brain. *Nature* 431 (7010), 757. doi:10.1038/431757a.
- Obleser, J., Boecker, H., Drzezga, A., Haslinger, B., Hennenlotter, A., Roettinger, M., et al., 2006. Vowel sound extraction in anterior superior temporal cortex. *Hum. Brain Mapp.* 27 (7), 562–571. doi:10.1002/hbm.20201.
- Oldfield, 1971. The assessment and analysis of handedness: the Edinburgh inventory. *Neuropsychologia* 9 (1), 97–113. doi:10.1016/0028-3932(71)90067-4.
- Paulesu, E., Démonet, J.F., Fazio, F., McCrory, E., Chanoine, V., Brunswick, N., et al., 2001. Dyslexia: cultural diversity and biological unity. *Science (New York, N.Y.)* 291 (5511), 2165–2167. doi:10.1126/science.1057179.
- Pernet, C., Andersson, J., Paulesu, E., Démonet, J.F., 2009. When all hypotheses are right: a multifocal account of dyslexia. *Hum. Brain Mapp.* 30 (7), 2278–2292. doi:10.1002/hbm.20670.
- Price, C.J., Mechelli, A., 2005. Reading and reading disturbance. *Curr. Opin. Neurobiol.* 15 (2), 231–238. doi:10.1016/j.conb.2005.03.003.
- Pugh, K.R., Mencl, W.E., Jenner, A.R., Katz, L., Frost, S.J., Lee, J.R., et al., 2000. Functional neuroimaging studies of reading and reading disability (developmental dyslexia). *Ment. Retard. Dev. Disabil. Res. Rev.* 6 (3), 207–213. doi:10.1002/1098-2779(2000)6:3<207::AID-MRDD8>3.0.CO;2-P.
- Richardson, F., Price, C., 2009. Structural MRI studies of language function in the undamaged brain. *Brain Struct. Funct.* 213 (6), 511–523. doi:10.1007/s00429-009-0211-y.
- Richlan, F., Kronbichler, M., Wimmer, H., 2009. Functional abnormalities in the dyslexic brain: a quantitative meta-analysis of neuroimaging studies. *Hum. Brain Mapp.* 30 (10), 3299–3308. doi:10.1002/hbm.20752.

- Rosen, G.D., Sherman, G.F., Galaburda, A.M., 1993. Neuronal subtypes and anatomic asymmetry: changes in neuronal number and cell-packing density. *Neuroscience* 56 (4), 833–839.
- Roux, F., Lubrano, V., Lauwers-Cances, V., Trémoulet, M., Mascott, C.R., Démonet, J., 2004. Intra-operative mapping of cortical areas involved in reading in mono- and bilingual patients. *Brain* 127 (Pt 8), 1796–1810. doi:10.1093/brain/awh204.
- Rumsey, J.M., Donohue, B.C., Brady, D.R., Nace, K., Giedd, J.N., Andreason, P., 1997. A magnetic resonance imaging study of planum temporale asymmetry in men with developmental dyslexia. *Arch. Neurol.* 54 (12), 1481–1489.
- Salat, D.H., Buckner, R.L., Snyder, A.Z., Greve, D.N., Desikan, R.S., Busa, E., et al., 2004. Thinning of the cerebral cortex in aging. *Cereb. Cortex* 14 (7), 721–730. doi:10.1093/cercor/bhh032.
- Shaw, P., Greenstein, D., Lerch, J., Clasen, L., Lenroot, R., Gogtay, N., et al., 2006. Intellectual ability and cortical development in children and adolescents. *Nature* 440 (7084), 676–679. doi:10.1038/nature04513.
- Shaywitz, S.E., Shaywitz, B.A., Pugh, K.R., Fulbright, R.K., Constable, R.T., Mencl, W.E., et al., 1998. Functional disruption in the organization of the brain for reading in dyslexia. *Proc. Natl. Acad. Sci. U. S. A.* 95 (5), 2636–2641 (VL - 95).
- Silani, G., Frith, U., Demonet, J., Fazio, F., Perani, D., Price, C., et al., 2005. Brain abnormalities underlying altered activation in dyslexia: a voxel based morphometry study. *Brain* 128 (Pt 10), 2453–2461. doi:10.1093/brain/awh579.
- Sled, J.G., Zijdenbos, A.P., Evans, A.C., 1998. A nonparametric method for automatic correction of intensity nonuniformity in MRI data. *IEEE Trans. Med. Imaging* 17 (1), 87–97. doi:10.1109/42.668698.
- Sowell, E.R., Thompson, P.M., Toga, A.W., 2004. Mapping changes in the human cortex throughout the span of life. *Neuroscientist* 10 (4), 372–392. doi:10.1177/1073858404263960.
- Sowell, E.R., Kan, E., Yoshii, J., Thompson, P.M., Bansal, R., Xu, D., et al., 2008. Thinning of sensorimotor cortices in children with Tourette syndrome. *Nat. Neurosci.* 11 (6), 637–639. doi:10.1038/nn.2121.
- Steinbrink, C., Vogt, K., Kastrup, A., Müller, H., Juengling, F., Kassubek, J., et al., 2008. The contribution of white and gray matter differences to developmental dyslexia: Insights from DTI and VBM at 3.0 T. *Neuropsychologia* 46 (13), 3170–3178. doi:10.1016/j.neuropsychologia.2008.07.015.
- Turkeltaub, P.E., Eden, G.F., Jones, K.M., Zeffiro, T.A., 2002. Meta-analysis of the functional neuroanatomy of single-word reading: method and validation. *NeuroImage* 16 (3, Part 1), 765–780. doi:10.1006/nimg.2002.1131.
- Turkeltaub, P.E., Gareau, L., Flowers, D.L., Zeffiro, T.A., Eden, G.F., 2003. Development of neural mechanisms for reading. *Nat. Neurosci.* 6 (7), 767–773. doi:10.1038/nn1065.
- Vinckenbosch, E., Robichon, F., Eliez, S., 2005. Gray matter alteration in dyslexia: converging evidence from volumetric and voxel-by-voxel MRI analyses. *Neuropsychologia* 43 (3), 324–331. doi:10.1016/j.neuropsychologia.2004.06.023.
- Wechsler, D., 2001. Wechsler test of adult reading. The Psychological Corporation, San Antonio, Texas.